REVIEW ARTICLE

FIXED PARTIAL DENTURE REMOVAL – WHEN, WHY AND HOW?

Author:

[1]Dr. Jibi Joseph
[2]Dr. Eldo Koshy
[3]Dr. Anu Anna Paul
[4]Dr. Sheryl Roy

[1]MDS, Prosthodontics
Dr. Koshy's Dental Implant Clinic
Kochi

[2]MDS, Prosthodontics
Dr. Koshy's Dental Implant Clinic
Kochi

[3]Chief Dental Surgeon
Dr. Koshy's Dental Implant Clinic
Kochi

[4]General Dentist
Dr. Koshy's Dental Implant Clinic
Kochi

ABSTRACT

Permanently cemented restorations may need to be removed for various reasons, such as elimination of secondary caries beneath the crown, endodontic treatment of a tooth with irreversible pulpitis, or removal of a fixed partial prosthesis with a loosened retainer at one end. However, disassembly of a fixed prosthesis is always an unpredictable procedure that may end in complications. The aim of this paper is to explain different methods of removal systems, and when and why they might be considered.

Keyword: Cementation failure, Ultrasonic, Jack-screw, Disassembly, Crown-splitter.

J Ind Dent Assoc Kochi 2022;4(2):20-6.

INTRODUCTION

The use of crowns and bridgework to restore a patient's dentition is a common procedure performed by dentists. Despite advancements in the materials and methods used to manufacture such restorations, as well as the cements used to keep them in place, crowns and bridges deteriorate and must be replaced. The reasons for failure are multiple and can be classified as1,2.

These findings emphasize the importance of inspecting crown and bridgework for indicators of failure on a frequent basis (Table1). In the interproximal regions, bitewing radiographs can reveal information on the marginal fit of restorations and retainers. On occlusal loading, thorough examination may reveal the characteristic appearance of bubbles emerging at the loose retainer's edge.

Biological
- Caries
- Endodontic treatment
- Endodontic re-treatment
- Periodontal
- Occlusion
- Metal allergies

Mechanical
- Cementation failure
- Defective margins
- Post and core failure under crowns or fixed bridges
- Precision attachment breakages
- Fractured porcelain facings

Aesthetics
- Colour
- Contour

Table 1: Reasons for fixed prosthesis failure

Treatment must be carefully planned, designed, and executed. Long-term success requires patient maintenance with good plaque management.[3]

Considerations prior to crown and bridge disassembly[4]

1. Medical contraindications
2. Restorability of retainer(s)
3. Periodontal status
4. Intra oral access
5. Status of underlying core
6. Cement lute used
7. Crown and bridge materials

Crown and bridge disassembly classification

There are number of mechanisms available for disassembling crown and bridge. It would be helpful and easier for the general practitioners if these mechanisms are classified into groups. Liam D Addy has classified different crown removal systems into groups in his article (Table2). These include[3] –

Conservative: prosthesis remain intact

Semiconservative: minor damages to the prosthesis. It could be potentially reused.

Destructive: prosthesis damaged and not reusable.

In general, conservative crown and bridge removers work by giving a percussion or traction force to the prosthesis, breaking the luting cement and allowing it to be removed in one piece. Cutting a small hole in the prosthesis allows a force to be placed between the

Conservative	Semi-conservative	Destructive
1. *Richwill Crown and Bridge Remover* 2. Ultrasonic 3. Pneumatic (KaVo) *CORONAflex®*) 4. Sliding hammer 5. Crown tractors 6. Matrix bands	1. *Higa Bridge Remover* 2. *Wamkey®* 3. *Metalift Crown and Bridge Removal System*	Crown or bridge sectioning: 1. Tungsten Carbide Burs 2. Burs and *Christenson Crown Remover*

Table2: Classification of crown removal system

preparation and the bridge to break the luting cement, which is a semi-conservative approach. Destructive techniques involve sectioning of crown or bridge to enable it to be levered off.

Conservative techniques for prosthesis disassembly

Ultrasonic vibrations, either alone or in combination with other treatments, can be effective in removing restorations.[5] Siqvel and matrix band applied over the crown, burnished into the undercuts, and then drawn vertically can be a good approach for cautious removal[6] (Figure1A).

Richwill crown and bridge remover (Richwill Laboratories, Orange, CA) is a thermoplastic resin recommended for crown and bridge removal.[7,8] The resin is softened in hot water, and the patient is told to occlude until the resin block has shrunk to two-thirds of its original size. This is then chilled until it is firm using water from a triple spray syringe. After that, the patient is told to open his or her mouth quickly and forcibly. In conjunction with the use of ultrasonic energy, this procedure has been reported to be 100% successful for temporary crowns and 60% successful for dislodging cast restorations.[7] Before performing this treatment, it's important to think about what's opposing the restoration that requires removal, as well as the periodontal health of all the teeth involved (Figure1B).

Crown and bridge removers with sliding hammer designs are available in the market. To loosen the restoration, an appropriate point is picked to engage the crown margin, and then a weight is moved along the shaft in a series of short, fast taps. This technique is not recommended for patients with periodontally involved teeth owing to the risk of unintended extraction (Figure1C). They are therefore best recommended for cast metal restorations.[9]

The Pneumatic (CORONAflex) crown and bridge remover is an air-driven device that connects to standard dental airline and works by delivering a controlled low amplitude shock at its tip along the long axis of the abutment tooth (Figure1D). The loop is rib below the connector and the tip of the crown remover is placed on the bar. By removing the index finger from the air valve on the hand piece, the impact is activated. Clamps are also available with this



Figure 1A

Figure 1C

Figure 1B

Figure 1D

kit, in which clamps are fixed to individual crowns using auto- polymerizing resin and the impact is delivered via clamp to the crown.

Crown tractors grip the restoration with the aid of rubber grips and a powder designed to dislodge the restoration without damaging the restoration. This is usually used removing provisional crowns, crowns restored with temporary cement, crowns that are difficult to remove at the try-in stage.

Semi-conservative techniques for prosthesis disassembly

Semi-conservative approach to disassemble the prosthesis, requires a small amount of damage to the prosthesis. The advantage with this is that it allows a more controlled and less traumatic application of force to dislodge the casting.

The Metalift system works on the jack-screw principle: a precise hole is drilled into the occlusal surface of a cast restoration, the area around the hole is undermined, and then a threaded screw is twisted into the space (Figure2A).[10] When the instrument is stopped from advancing by contact with the underlying core, a thread is cut in the metal of the casting, and prolonged spinning of the screw causes a 'jacking force,' which displaces the crown from the preparation. This technique is used to remove metal ceramic crowns with a minimum metal thickness of 0.5mm.

WamkeysTM are small, narrow-shanked cams that come in three sizes. The physician drills a hole parallel to the occlusal surface and at the hypothesised level of the underlying core through the crown or retainer (Figure2B). A Wamkey of appropriate size is inserted, with the cam's widest surface parallel to the occlusal surface, until it is centrally located when rotated 90 degrees around the shank's axis. The force should be applied in the direction of crown or retainer insertion, which is easily dislodged. The restoration can be resurfaced and the hole sealed with plastic filler material.[3]

Figure 2A

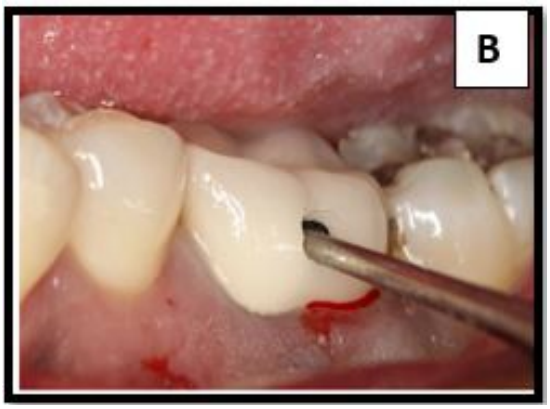

Figure 2B

Destructive techniques for prosthesis disassembly

Commonly practised method by most of the clinicians to remove the crown and bridge is by using a carbide or tungsten bur (Figure4). By confining the slot to the labial surface and disrupting the cement lute with an ultrasonic tool, space can be created to elevate the crown or bridge and keep it intact. When using adhesive cements, it may be required to cut through the lingual surface as well, which will entirely ruin the crown.[3] While attempting to remove the crown, a gauze piece must be reinserted to prevent the patient from aspirating it (Figure 3).

Figure 3

Figure 4

Figure 5

Figure 6

While excavators and Mitchell's trimmers can be employed, a Christenson crown remover is a handy tool for this final stage. The use of such a 'crown splitter' evenly distributes the split, decreasing stress on the tooth/core. The restorations that have been removed in this manner cannot be reused, but they can be relined and used as temporary restorations.[3]

A suture thread or dental floss can be tied to the bridge (Fixed prosthesis) before removing it to prevent its aspiration (Figure5).

Removal of Porcelain Crowns and Veneers

Lasers can be utilised to successfully debond porcelain laminate veneers and crowns as an alternative to standard removal techniques (such as handpieces and diamond burs). A veneer restoration can be adequately debonded in less than 2 minutes using an erbium laser at 2780-2940 nm (Figure6). The wavelength of the laser goes through the porcelain and is absorbed by the water in the luting agent, causing the resin to soften thermally. After the laser is applied, a mechanical remover (curette or crown remover) is used to remove the entire veneer.[11,12]

Retrieval of Implant Crowns

If an abutment screw loosens, the head of the abutment screw must be accurately found and accessed. This can be accomplished using a variety of techniques, including intraoral periapical radiography or cone beam computed tomography, staining the occlusal surface of the crown at the location of the abutment screw as a means of locating screw access, and creating a small access opening or slot within the crown to reach the abutment screw and tighten it without damaging the cemented crown.[13,14,15]

During wax-up, Prestipino et al[16] created a flat retrieval slot in the lingual marginal area of the crown-abutment interface. They inserted a flat-headed driver into the slot and rotated it clockwise, causing a torquing force that drove the abutment below while pushing the prosthesis higher, finally breaking the cement seal.

A process for fabricating a retrievable cemented restoration was described by Rajan and Gunaseelan. During the wax-up, casting, and ceramic application of the implant crown, a screwdriver is used to keep a screw access channel open. Excess cement extruded via the channel is removed once the crown is cemented, and the channel is sealed with composite resin. Uludag and Celik later used this technique to create a multiunit prosthesis.[17,18]

A technique for reaching an abutment screw in a cement-retained restoration was described in two clinical reports. Using a vacuum-formed transparent stent or guide, the approach tries to precisely establish the 3-dimensional position of the abutment screw. The guide is built above the cemented restoration's cast, with access holes inserted to aid in screw site visibility. The guide is put in the mouth for crown retrieval, and the crown is drilled through the access holes to locate the abutment screws.[19,20]

CONCLUSION

The discussion above has focussed on some specific devices and systems applicable to the area of interest. No universal system exists for the safe, intact removal of permanently cemented prostheses. Each clinical situation differs, and some circumstances may dictate the use of a combination of techniques. Success lies in careful treatment planning, none of the instruments are universally applicable. Some situations may require conservative approach while some destructive. Patient should be made aware, at the outset of the treatment, of the unpredictability of attempts at conservative and semi-conservative crown and bridge disassembly, and also the risks associated with it.

REFERENCES

1. Walton J, Gardner F, Agar J. A survey of crown and fixed partial denture failures: length of service and reasons for replacement. J Prosthet Dent 1986;56:416-21.
2. Reuter J, Brose MO. Failures in full crown retained dental bridges. Br Dent J 1984;157:61-3.
3. Addy LD, A Bartley, SJ Hayes. Crown and Bridge Disassembly-When, Why and How. Dent Update2007;34:140-50.
4. Trenter SC, Walmsley AD. Ultrasonic dental scaler: associated hazards. J Clin Periodontol 2003;30:95-101.
5. Abbot PV. Incidence of root fractures and methods used for post removal. Int Endod J 2002;15:313-18.
6. McCullock AJ. Dental demolition. Dent Update1992;19:255-62.
7. Wise MD. The causes of failure.In: Failure in the Restored dentition: Management and Treatment. London: Quintessence Publication:1995:pg13-31.
8. Oliva RA. Clinical evaluation of a new crown and fixed partial denture remover. J Prosthet Dent1980;44:267-69.
9. Rosenstiel SF, Land MF, Fujimoto J. Post operative care. In: Contemporary Fixed Prosthodontics 3rd ed. Missouri: Mosby Inc, 2001:pp.782-817.
10. Westerman RD. A new paradigm for the construction and service of fixed Prosthodontics. Dent Today1999;18:62-9.
11. Janardanan K, Varkey VK, Lovely M, Anuroopa A. Coronal disassembly systems and techniques: an overview. J Interdiscip Dent 2014;4(1):33-40.
12. Morford CK, Buu NC, Rechmann BM, Finzen FC, Sharma AB, Rechmann P. Er:YAG laser debonding of porcelain veneers. Lasers Surg Med 2011;43(10): 965-74.
13. Patil PG. A technique for repairing a loosening abutment screw for a cement-retained implant prosthesis. J Prosthodont. 2011;20(8):652-655.
14. Schwedhelm ER, Raigrodski AJ. A technique for locating implant abutment

screws of posterior cement-retained metal-ceramic restorations with ceramic occlusal surfaces.J Prosthet Dent. 2006;95(2):165-167.

15. Ichikawa T, Ishida O, Watanabe M, Tomotake Y, Wei H, Jianrong C. A new retrieval system for cement-retained implant superstructures: a technical report. J Prosthodont. 2008;17(6):487-489.

16. Prestipino V, Ingber A, Kravitz J, Whitehead GM. A practical approach for retrieving cement retained, implant-supported restorations. Quintessence Dent Technol.2001;24:182-187.

17. Rajan M, Gunaseelan R. Fabrication of a cement and screw-retained implant prosthesis. J Prosthet Dent. 2004;92(6):578-580.

18. Uludag B, Celik G. Fabrication of a cement- and screw-retained multiunit implant restoration. J Oral Implantol. 2006;32(5):248-250.

19. Kheur M, Harianawala H, Kantharia N, Sethi T, Jambhekar S. Access to abutment screw in cement retained restorations: a clinical tip. J Clin Diagn Res.2015;9(2):ZD17-ZD18.

20. Doerr J. Simplified technique for retrieving cemented implant restorations. J Prosthet Dent. 2002;88(3):352-353.